

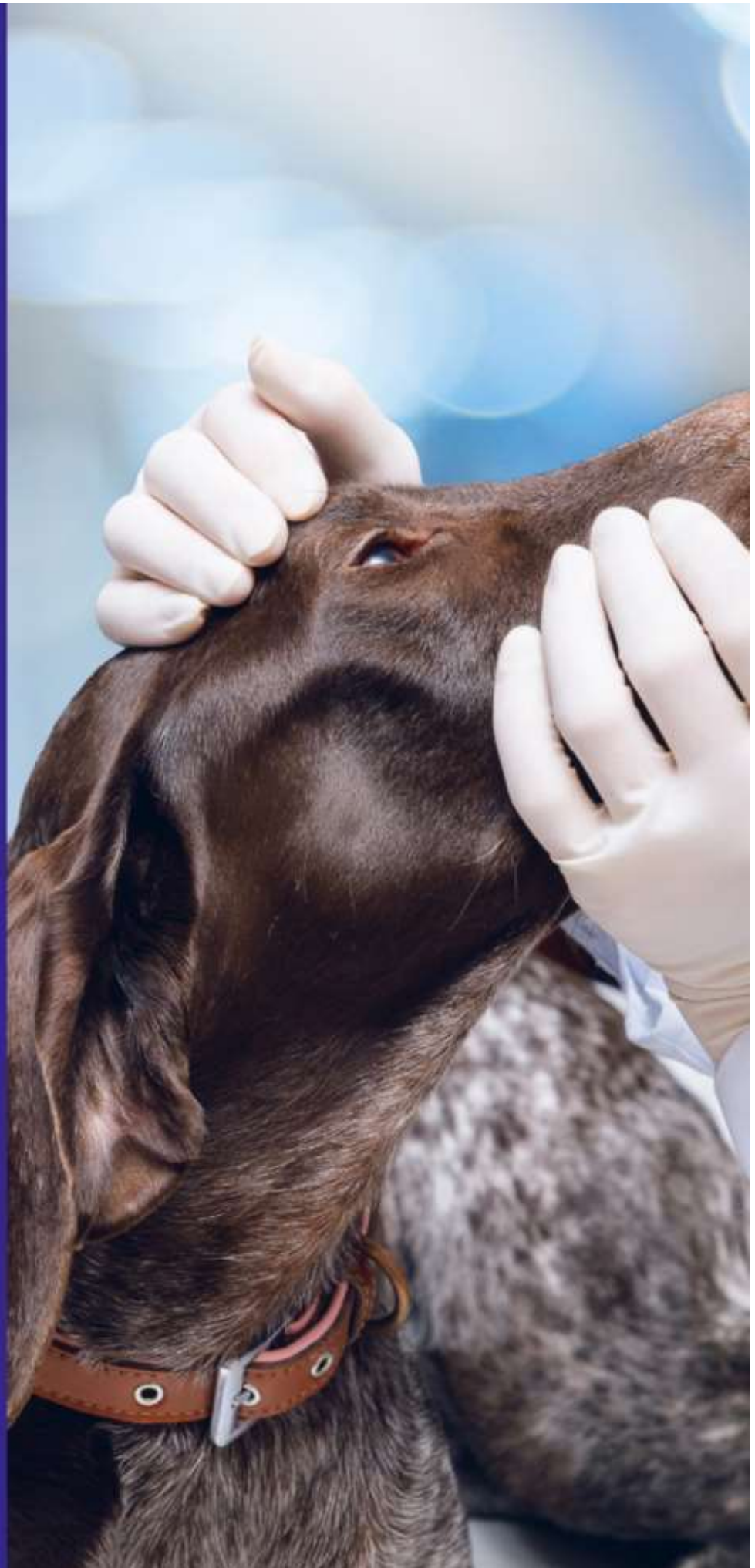14th Edition

The Blue Book

OCULAR DISORDERS
PRESUMED TO BE INHERITED
IN PUREBRED DOGS

GENETICS COMMITTEE OF
THE AMERICAN COLLEGE
OF VETERINARY
OPHTHALMOLOGISTS

2022



Foreword

Ocular disorders, proven or presumed to be inherited in purebred dogs, have been a topic of intense dialogue by Diplomates of the American College of Veterinary Ophthalmologists (ACVO) for many years. Discussions commenced in the latter half of the 20th century during the early days of this College's inception, have continued into the 21st century, and will no doubt continue for years to come. Our knowledge of the existence, nature, progression, and inheritance of ocular disorders continues to expand as this field of veterinary science evolves. The Genetics Committee of the ACVO was originally formed in response to requests by registries, breed groups, and veterinarians, with the intent to provide a scientific advisory panel and guidelines regarding ocular disorders in purebred dogs. The Genetics Committee of today remains engaged in an ongoing effort to update information on ocular disorders for this purpose.

The content of this production has originated from several sources as the ACVO recently created a Companion Animal Eye Registry (CAER), which is a joint effort between the Orthopedic Foundation for Animals (OFA) and the ACVO. The addition of eye examination results to the OFA database makes the OFA the most complete source of canine health screening results in the world, allowing responsible breeders to make more informed breeding decisions in an effort to reduce the incidence of inherited disease.

The generation of statistical information is made possible by the efforts of dedicated breeders of purebred dogs who present their dogs to Diplomates of the ACVO for an OFA Companion Animal Eye Registry examination. The research copies of these examinations are then conscientiously submitted to OFA by the examining Veterinary Ophthalmologists. These data generate annual statistics. The statistics for each breed are then reviewed by the Genetics Committee for the most recent year and from the previous 5 years. Recommendations regarding the ocular disorders listed for each breed and the breeding advice are compiled following guidelines detailed elsewhere in this publication. A comprehensive review of the scientific literature since the last published edition was undertaken by all committee members. The scientific articles and breed disorders from the statistical and literature review have been added to the information on each breed in the production of this document. The collective educated clinical experience of the committee members is utilized to reach a consensus of opinion in areas where there remains a paucity of hard scientific proof regarding certain identified breed problems.

The current Genetics Committee has instituted an annual scientific literature search, in addition to the previously established yearly statistical data review. This information is compiled and submitted in an effort to maintain a bank of current information for future editions and versions of this document. The content of all editions past, present, and future will remain dynamic and ever changing as more precise technologies advance the study of the canine genome, as continued scientific research expands our knowledge, and as the database grows.

It is an honor and a privilege to serve the ACVO, our fellow Diplomates, reputable dog breeders, and our most trusted canine companions in this endeavor.

Genetics Committee 2023

Sony Kuhn Asif (Chair), Melissa Kubai (Co-chair), Freya Mowat (Past Chair), Ursula Dietrich, Katelyn Fentiman, Simone Iwabe, Sami Pederson, Emily Sharp

Gus Aguirre – Advisor

Simon Petersen-Jones – ECVO Advisor

Katie Diehl – OFA Liaison

14th Edition 2022 Version Acknowledgements

The following groups and individuals deserve credit for the production of this edition of Ocular Disorders Presumed to be Inherited in Purebred Dogs ("The Blue Book"):

The ACVO Board of Regents

Genetics Committee Chairs Dr. Andras Komaromy 2006-2008, Dr. Katie Diehl (2009-2011), Dr. Jacqueline Pearce (2011-2012), Dr. Carrie Breaux (2011-2013), Dr. Kenneth Pierce (2014), Dr. Wendy Townsend (2015), Ellen Belknap (2016), Jessica Meekins (2017), Renee Carter (2018), Adam King (2019), Jane Ashley Huey (2020), Katelyn Fentiman (2021), Freya Mowat (2022) and all previous Genetics Committee members

Eddie Dziuk, Chief Operating Officer, and Erika Werne, CAER Program Manager, for the OFA

Introduction

What is the purpose of this book?

The Orthopedic Foundation for Animals (OFA), Canine Eye Registration Foundation (CERF), other breed registry groups, breed clubs, and practicing veterinarians have requested that the American College of Veterinary Ophthalmologists (ACVO) provide a scientific advisory panel to furnish guidelines regarding ocular disorders of major concern to purebred dogs. The Genetics Committee of the ACVO was formed in response to these requests and is engaged in an ongoing effort to update information on ocular disorders proven or suspected to be hereditary in purebred dogs. The compendium of ocular disorders and breeding recommendations which follow are interim guidelines. They are reviewed regularly and revised whenever additional information becomes available.

How can this information be used?

National and international breed clubs are encouraged to submit their input regarding breeding decisions for ocular disorders found in their breeds. **Local breed clubs** can participate by encouraging and organizing ocular examination clinics and forwarding their requests and concerns to their national organization. **Practicing veterinarians** are encouraged to contribute by informing all owners of potential breeding animals of the value and availability of ocular examinations, prior to breeding. Information regarding ocular disorders found in litters or individuals can be forwarded to the Genetics Committee via any ACVO diplomate. **Individual breeders** wishing to uphold high ethical standards for the improvement of their breed are urged to contribute by annual examination of their breeding animals and by encouraging the same from other breeders. Further information can be obtained from the Orthopedic Foundation for Animals (OFA): 2300 E Nifong Boulevard, Columbia, MO, 65201-3806, 573-442-0418. Only through increased awareness of the problems and a sustained cooperative effort to disseminate accurate information, will we be able to control and/or eliminate hereditary eye diseases in purebred dogs.

How do we identify an inherited eye disease?

Although there are noteworthy exceptions, most of the ocular diseases of dogs which are presumed to be hereditary have not been adequately documented. Genetic studies require examination of large numbers of related animals in order to characterize the disorder (age of onset, characteristic appearance, rate of progression) and to define the mode of inheritance (recessive, dominant). In a clinical situation, related animals are frequently not available for examination once a disorder suspected to be inherited is identified in an individual dog. Maintaining a number of dogs for controlled breeding trials through several generations is a long and costly process. Both of these obstacles are compounded by the fact that many ocular conditions do not develop until later in life. Due to the potential for disease to arise from inherited genetic defects at any age, the Genetics Committee recommends annual eye exams.

Until the genetic basis of an ocular disorder is defined in a published report, we rely on what statistical information is available from registry organizations, informed opinions and consensus from ACVO diplomates, and must satisfy ourselves with terms like "presumed inherited" and "suspected to be inherited." Several companies provide information on genetic testing which greatly assists in providing more information and data to aid in defining the canine genetics of ocular diseases.

When do we suspect that a disorder is inherited in a given breed?

- When the frequency is greater than in other breeds
- When the frequency increases in a given breed as a whole
- When the frequency is greater in related dogs within a breed
- When it has a characteristic appearance and location
- When it has a characteristic age of onset and course of progression (predictable stages of development and time for each stage to develop)
- When it looks identical to an entity which has been proven to be inherited in another breed

Special thank you to the “Father of Veterinary Medical Genetics,” Donald F. Patterson, DVM, DSc. Dr. Patterson, who died in 2013, was Emeritus Professor of Medicine and Medical Genetics, University of Pennsylvania School of Veterinary Medicine and Emeritus Professor of Human Genetics, University of Pennsylvania School of Medicine. These guidelines on the heritability of disorders in dogs are based on his lectures and publications.

Guidelines Used by the ACVO Genetics Committee in Making Breeding Recommendations

In this book, we chose the term "**BREEDING ADVICE**" and intentionally avoided the words "certifiable" and "registerable." The ACVO does not serve as a registry organization. Registry organizations operate independently of the ACVO and set their own standards for registration. However, the OFA does follow the guidelines set forth by the ACVO Genetics Committee in this publication. Any registry organization may use the information in this compendium and results of examinations performed by ACVO Diplomates in the registering of animals with regard to breeding suitability as they see fit.

It is important to recognize that the sensitivity of genetic disorder detection is greater when large numbers of dogs are examined. The extensive number of disorders listed in this book for some breeds may reflect the popularity of the breed and the numbers of animals evaluated. Conversely, the lack of disorders listed for other breeds often reflects only the paucity of examinations reported for each breed. For these reasons, the ACVO Genetics Committee strongly recommends annual evaluations of dogs of all breeds as the imperative first step in the control of hereditary ocular disorders. We would like to acknowledge the contribution of the Orthopedic Foundation for Animals (OFA) and Canine Eye Registration Foundation (CERF) for providing statistical summaries of ophthalmic examinations from their files.

For each breed, specific ocular disorders have been listed which are known or suspected to be inherited based on one or more of the following criteria:

- 1) There are published reports in the scientific literature regarding a condition in a particular breed with evidence of inheritance.
- 2) The incidence of affected animals (from OFA and CERF reports) is greater than or equal to 1% of the examined population with a minimum of five affected animals per five year period. Regardless of the population of dogs examined, if 50 or more affected individuals are identified in a five year period, the entity will be listed for that breed.
- 3) A specific request from a breed club that a condition be included for their breed may be considered at the ACVO annual meeting of the Genetics Committee if information is received by August 1. Such requests are reviewed critically and must include specific documentation as to the disorder in question and the numbers seen. Further information from the breed club may be requested. The request must receive agreement by a majority of the committee.
- 4) There is overwhelming opinion by a majority of the Genetics Committee members that clinical experience by ACVO Diplomates would indicate a particular condition should be listed for a breed, in spite of the absence of direct evidence of affected animals on OFA or CERF reports.
- 5) Results of genetic laboratory research and genetic testing.

The "Breeding Advice" given is determined by the significance of the condition to vision and/or very strong evidence of heritability:

Two categories of advice regarding breeding have been established:

NO: Substantial evidence exists to support the heritability of this entity AND/OR the entity represents a potential compromise of vision or other ocular function.

BREEDER OPTION: Entity is suspected to be inherited but does not represent potential compromise of vision or other ocular function.

When the breeding advice is "**NO**," even a minor clinical form of the entity would make this animal unsuitable for breeding. When the advice is "**BREEDER OPTION**," caution is advised. In time, it may be appropriate to modify this stand to "**NO**" based on accumulated evidence. If, in time, it becomes apparent that there is insufficient evidence that an entity is inherited, it may be deleted from the list.

There are currently eleven disorders for which there is an unequivocal recommendation against breeding in all breeds:

These are conditions which frequently result in blindness and for which there is definite evidence of heritability in one or more breeds. However, these disorders will not be listed on the individual breed page for a given breed, unless they also meet the criteria described above.

- **Keratoconjunctivitis sicca (KCS)** – Breeding is not recommended for any animal demonstrating keratitis consistent with KCS. The prudent approach is to assume KCS to be hereditary except in cases suspected to be non-genetic in origin. See *note.
- **Glaucoma** – See *note.
- **Persistent Pupillary Membranes**
 - **Iris to Lens**
 - **Iris to Cornea**
 - **Iris Sheets**
 - **Endothelial Opacity/No Strands**
- **Cataract** – Breeding is not recommended for any animal demonstrating partial or complete opacity of the lens or its capsule. See *note.
- **Lens luxation or subluxation** – See *note.
- **Persistent hyperplastic primary vitreous (PHPV)/persistent hyperplastic tunica vasculosa lentis (PHTVL)** – See *note.
- **Retinal detachment** – See *note.
- **Retinal atrophy – generalized (PRA)** - Breeding is not advised for any animal demonstrating bilaterally symmetric retinal degeneration (considered to be PRA unless proven otherwise).
- **Retinal dysplasia, geographic or detached forms** – See *note.
- **Optic nerve coloboma**
- **Optic nerve hypoplasia**

**Note: The prudent approach of these disorders is to assume they are hereditary except in cases specifically known to be associated with trauma, other causes of ocular inflammation, specific metabolic diseases, or nutritional deficiencies.*

The following breeds are recommended to have a preliminary examination prior to initial pharmacological dilation to best facilitate identification of these disorders:

Dalmatian – iris hypoplasia/sphincter dysplasia

Australian Shepherd – iris coloboma

Miniature American Shepherd/Miniature Australian Shepherd – iris coloboma

Toy Australian Shepherd – iris coloboma

Mudi – iris hypoplasia/iris coloboma

What can be detected during an Eye Certification Examination?

A routine eye screening examination includes indirect ophthalmoscopy and slit lamp biomicroscopy following pharmacological dilation of the pupils. Gonioscopy, tonometry, Schirmer tear test, electroretinography, and ultrasonography are not routinely performed; thus, dogs with goniodysgenesis, glaucoma, keratoconjunctivitis sicca, or some early cases of progressive retinal atrophy might not be detected without further testing.

The diagnoses obtained during an ophthalmic eye certification examination refer only to the **phenotype** (clinical appearance) of an animal. Thus, it is possible for a clinically normal animal to be a carrier (abnormal **genotype**) of genetic abnormalities.

An individual ACVO Diplomate may disagree with the breeding advice contained in this compendium. It is appropriate for this examiner to contact the ACVO Genetics Committee to voice disagreement, initiate change, or suggest additions. The members of the Genetics Committee represent the ACVO but acknowledge that the information generated for a breed may not agree with the knowledge and clinical experience of every individual ACVO Diplomate.

What is the role of the responsible dog breeder?

The final beneficiary of the information in this book is the dog breeder. It is up to the conscientious breeder to use this information along with other criteria in selecting which animals to breed. To assist this determination, current certification is recommended. Animals currently free of heritable eye disease will be issued a certificate on receipt of the examination/application by OFA. To avoid confusion between a normal animal (no evidence of heritable eye disorders) and one that may have a minor fault coming under the advice of Breeder Option, the Breeder Option category will be printed on the certificate. This is intended to stimulate conversation as to the specific nature of the Breeder Option condition found in that particular animal, allowing breeders using a dog in a breeding program to make an informed decision.

There are many ocular conditions which are a direct result of selection for a facial conformation considered desirable by breeders.

These include:

- Entropion
- Ectropion
- Macroblepharon
- Exposure keratopathy syndrome

Facial conformation with excessively prominent eyes, heavy facial folds, or eyelids which are either inverted or everted predispose animals to corneal irritation, discomfort, and if left untreated, can lead to loss of vision. A responsible breeding program should recognize and select away from these exaggerated facial features.

THE ROLE OF GENETIC TESTING IN THE DETECTION OF OCULAR DISEASE

Genetic testing plays a very important role in the diagnosis of disease. However, it is important to be aware of the limitations of genetic testing and understand its role in the detection and control of genetically inherited diseases.

Genetically inherited diseases are caused by a deleterious sequence change (mutation) in the DNA that results in an abnormal protein (protein can be absent, have insufficient function, or have an abnormal function) that results in disease.

Genetic tests are developed by comparing the DNA sequence of a normal animal to that of an animal with disease. This allows the identification of a particular DNA sequence that can be causally associated with the disease. This is an extremely powerful tool that, in some cases, allows for identification of disease even before it is evident clinically.

However, a particular test is only capable of detecting the DNA sequence it was designed to detect. That is, the DNA test only tests for a specific change in the DNA that can cause disease. For example, a DNA test specific for the *PDE6B* gene mutation (responsible for the rcd1 form of PRA in the Irish Setter) will not detect any abnormalities in other breeds or mixed breeds that have other mutations in the same gene. Thus the specificity of a DNA test is also its limitation, and in the case of PRA in Irish Setters it is specific for the Irish Setter defect and not for any other defects.

In polygenic disorders, a genetic test cannot evaluate the integrity of all the proteins that make up a particular cellular process. Thus, it is possible for a DNA test that has been associated with a disease to be normal and yet the disease can still be present. The disease could be caused by an abnormality in one of the other genes that are involved with that particular cellular process. The defect in the other protein still results in an abnormal cellular process, which still results in disease. A perfect example of this is observed in oculo-skeletal dysplasia in Labrador Retrievers and Samoyed dogs. In both breeds the diseases are clinically identical, yet caused by mutations in different genes involved in fibril formation of a specific kind of collagen molecule.

Thus, obtaining a DNA test that is normal does not guarantee absence of disease. It only guarantees that the particular change the DNA test was designed to detect is not present, and that disease from that particular change will not occur. This is why genetic testing should be combined with ophthalmic examination for maximum efficacy. An ophthalmic exam evaluates the sum total or "result" of all the cellular processes required to maintain ocular health and result in vision, and is an essential part of the ocular wellness exam to ensure that other important clinically recognizable diseases are not present.

Breeder Option Codes

A – Eyelids

- A1 Entropion
- A2 Ectropion
- A3 Distichiasis
- A4 Ectopic Cilia
- A6 Imperforate Lacrimal Punctum

B – Nictans

- B1 Cartilage Anomaly/Eversion
- B2 Gland Prolapse

C – Cornea

- C1 Corneal Dystrophy – Epithelial/Stromal
- C2 Corneal Dystrophy – Endothelial
- C4 Pigmentary Keratitis/Keratopathy

D – Uvea

- D1a Uveal Cyst – Free Floating
- D1b Uveal Cyst – Single
- D1c Uveal Cyst – Multiple
- D2 Iris Coloboma
- D3 Persistent Pupillary Membranes – Iris to Iris
- D4 Iris Hypoplasia

E – Lens

- E1 Cataract – Suspect Not Inherited
- E2 Posterior Y Tip Suture Opacities

F – Vitreous

- F1 Persistent Hyaloid Artery
- F2a Vitreous Degeneration – Syneresis
- F2b Vitreous Degeneration – Anterior Chamber

G – Fundus

- G1 Retinal Dysplasia – Folds
- G5 Micropapilla
- G6a CMR-Type Retinopathy
- G6b Retinopathy

Glossary of Terms

(For more detailed definitions, the reader is referred to medical and genetic scientific texts.)

Achromatopsia: see **Day blindness**

Canine multifocal retinopathy: characterized by numerous distinct (i.e. multifocal), roughly circular patches of elevated retina (multifocal bullous retinal detachments). The condition includes numerous distinct (i.e. multi-focal), roughly circular patches of elevated retina with accumulation of material that produces gray-tan-pink colored lesions (multifocal bullous retinal detachments). These lesions, looking somewhat like blisters, vary in location and size, although typically they are present in both eyes of the affected dog.

The disease generally develops in young dogs and might not progress or progress slowly, or may appear to heal with discrete areas of tapetal hyper-reflectivity or hyperpigmentation. Most dogs exhibit no noticeable problem with vision despite their abnormal appearing retinas.

Cataract: any opacity of the lens and/or its capsule, regardless of size or location within the lens. Cataracts are assumed to be hereditary unless associated with known trauma, ocular inflammation, specific metabolic diseases, or nutritional deficiencies.

Ceroid lipofuscinosis: an inherited disease of man and animals characterized by the accumulation of lipopigment in various tissues of the body including the eye. It results in progressive neurologic disease including blindness. (Also called Batten's disease.)

Choroidal hypoplasia: a congenital, inherited, non-progressive defect primarily affecting the choroid resulting in some or all of the following: decreased or lack of pigment in the retinal pigment epithelium or choroid, tapetal thinning, and reduced or abnormal choroidal blood vessels.

Chronic superficial keratitis (CSK): see **Pannus**

Collie eye anomaly: a congenital syndrome of ocular anomalies characterized by bilateral and often symmetrical defects including any combination of **choroidal hypoplasia**, **coloboma**, and **retinal detachment(s)**.

Coloboma: a congenital abnormality in ocular development usually characterized by focal absence of tissue, commonly (though not exclusively) located at the 6 o'clock position associated with failure of closure of the optic fissure.

Cone degeneration: the loss of photopic vision caused by selective degeneration of the cone photoreceptors. Also known as day blindness, hemeralopia, or achromatopsia.

Corneal degeneration: opacification of one or more of the corneal layers frequently resulting from deposition of lipid or mineral and occurring secondary to chronic inflammation.

Corneal dystrophy: non-inflammatory corneal opacity (white to gray) present in one or more of the corneal layers (**epithelium**, **stroma**, **endothelium**). The term dystrophy implies an inherited condition. It is usually bilateral although not necessarily symmetrical and the onset in one eye may precede the other.

Corneal dystrophy - endothelial: breed-related loss or dysfunction of corneal endothelial cells resulting in bilateral, progressive corneal edema.

Corneal dystrophy - epithelial, stromal: breed-related, non-inflammatory, white to silver-colored opacification of the corneal epithelium and/or stroma frequently resulting from deposition of lipid.

Day blindness: see **Cone degeneration**

Dental-skeletal-retinal anomaly (DSRA): Dental-Skeletal-Retinal-Anomaly (DSRA) is a syndromic condition documented in the Cane Corso. This condition is associated with a MIA3 splice defect that has been identified in all affected dogs with an autosomal recessive inheritance pattern. Clinically affected dogs present with dwarfism, dental abnormalities including loss of enamel and tooth discoloration, as well as early onset retinal atrophy.

Dermoid: a congenital, non-cancerous growth occurring on the cornea, conjunctiva, or eyelid typified by the presence of skin-like structures.

Distichiasis: the presence of abnormally oriented eyelashes, frequently protruding from Meibomian gland ductal openings.

Dry eye: see **Keratoconjunctivitis sicca**

Dysplasia: abnormality of development.

Dystrophy: non-inflammatory, developmental, nutritional, or metabolic abnormality; dystrophy implies a possible hereditary basis and is usually bilateral.

Ectopic cilia: aberrant hairs emerging through the palpebral conjunctiva which often causes ocular discomfort and corneal disease.

Ectropion: a conformational defect resulting in eversion of the eyelid margin, which may cause ocular irritation due to exposure. It is likely that ectropion is influenced by several factors defining the skin and other structures, which make up the eyelids, orbital contents, and conformation of the skull.

Entropion: a conformational defect resulting in inversion of the eyelid margin which may cause ocular irritation. It is likely that entropion is influenced by several factors defining the skin and other structures, which make up the eyelids, orbital contents, and conformation of the skull.

Euryblepharon: an exceptionally long eyelid marginal length, which may lead to Ectropion or Entropion. Euryblepharon is synonymous with the term macropalpebral fissure.

Exposure/pigmentary keratitis: a condition characterized by variable degrees of superficial vascularization, fibrosis, and/or pigmentation of the cornea. May be associated with excessive exposure/irritation of the globe due to shallow orbits, lower eyelid medial entropion, lagophthalmos, and macropalpebral fissure.

Glaucoma: characterized by an elevation of intraocular pressure (IOP) which causes optic nerve and retinal degeneration and results in blindness. Diagnosis and classification of glaucoma requires tonometry and gonioscopy, which are not part of a routine eye certification examination.

Glaucoma, pigmentary: see **Ocular melanosis**

Goniodysgenesis: congenital anomaly characterized by the persistence of a variably fenestrated sheet of uveal tissue spanning the iridocorneal angle, extending from the iris base to the peripheral cornea.

Diagnosis is by gonioscopy, which is not part of a routine eye certification examination.

Hemeralopia: see **Cone degeneration**

Imperforate lacrimal punctum: developmental anomaly resulting in an imperforate opening of the lacrimal puncta. An imperforate lower punctum may result in epiphora, an overflow of tears onto the face.

Iridocorneal angle: the junction between the iris and the cornea; the drainage angle. Aqueous humor leaves the anterior chamber via the trabecular meshwork within the iridocorneal angle into the venous circulation.

Iris coloboma: a congenital abnormality in iris development usually characterized by a full-thickness defect in iris tissue, commonly (though not exclusively) located at the 6 o'clock position associated with failure of closure of the optic fissure. A partial-thickness defect in iris tissue should be recorded as iris hypoplasia on the eye certification form.

Iris cyst: see **Uveal cyst**

Iris hypoplasia: a congenital abnormality in iris development usually characterized by a reduced quantity of tissue identified as a partial-thickness defect in iris tissue. Full-thickness iris hypoplasia is rare and should be recorded as an iris coloboma on the eye certification form.

Iris melanoma: see **Uveal melanoma**

Iris sphincter dysplasia: a congenital abnormality in iris development usually characterized by a full-thickness defect in iris tissue at the level of the iris sphincter, causing pupillary dilation. This abnormality has been noted in the Dalmatian breed.

Keratitis: inflammation of the cornea.

Keratitis, punctate: inflammation of the cornea accompanied by multifocal, coalescing areas of stromal corneal ulceration of variable depth.

Keratoconjunctivitis sicca (KCS): an abnormality of the tear film attributed to deficiency of the aqueous portion of the tears. Progressive KCS may result in ocular surface irritation and/or vision impairment via corneal opacification. Also called dry eye. The test for this condition is the Schirmer Tear Test, which is not part of a routine eye certification examination.

Lens subluxation/luxation: partial (subluxation) or complete displacement of the lens from the normal anatomic site. Lens luxation may result in elevated intraocular pressure (secondary glaucoma), causing vision impairment, pain, and/or retinal detachment.

Lenticonus: an anomaly of the lens in which the anterior or posterior surface protrudes in a conical form; usually congenital.

Macroblepharon: an exceptionally large palpebral fissure. Macroblepharon in conjunction with laxity of the lateral canthal structures may lead to lower lid ectropion and upper lid entropion. Either of these conditions may lead to severe ocular irritation.

Merle: an incompletely dominant phenotype in which heterozygous (M/m) dogs exhibit a coat color phenotype of various dilute color patches, while homozygous (M/M) dogs exhibit marked hypopigmentation and ocular defects, including microphthalmia, blindness and colobomas, and deafness. Deafness and

ocular defects are sometimes seen in heterozygous individuals.

Micropapilla: a congenital anomaly which results in a small optic disk diameter without vision loss. Contrast with optic nerve hypoplasia, which may have a similar ophthalmoscopic appearance with vision loss.

Microphakia: a congenital anomaly in which there is an abnormally small lens.

Microphthalmos: a congenital anomaly in which the globe is abnormally small. Commonly associated with multiple ocular malformations and when severe, may affect vision.

Nictitans cartilage anomaly/eversion: a congenital anomaly in the nictitating membrane in which the T-shaped cartilage is malformed and/or folded.

Nictitans gland prolapse: protrusion of the tear-producing gland of the nictitating membrane from its normal position posterior to the nictitating membrane, to a position superior to the free margin of this structure.

Nodular granulomatous episclerokeratitis (NGE): an inflammatory disorder of the sclera and episclera, with occasional corneal involvement, characterized by granulomatous infiltrates. Previously known as **Proliferative keratoconjunctivitis**. This condition is most commonly seen in the Collie.

Nyctalopia: loss of scotopic (night) vision. Causes include genetic defects in photoreceptors and in retinal pigment epithelium, either dystrophy or degeneration of affected cells.

Ocular melanosis: progressive bilateral and sometimes asymmetrical increase in pigmentation with melanocytic accumulation the uveal tract and adjacent tissues. Ultimately progresses to glaucoma and loss of vision in most cases (melanocytic glaucoma). Not associated with systemic disease or metastases. Most often recognized in Cairn Terriers.

Optic nerve coloboma: a congenital abnormality of the optic nerve commonly associated with failure of closure of the optic fissure, resulting in a defect in the optic nerve in the anterior-posterior plane. May result in partial or total vision loss.

Optic nerve hypoplasia: a congenital anomaly, which results in a small optic disk diameter and vision loss. Contrast with micropapilla, which may have a similar ophthalmoscopic appearance but without loss of vision.

Pannus: a bilateral inflammatory disease of the cornea which usually starts as a grayish haze to the inferior or inferiotemporal cornea, followed by the formation of a vascularized subepithelial opacity that begins to spread toward the central cornea; pigmentation may follow the vascularization. If severe, vision impairment occurs. Plasma cell infiltration of the nictitans may occur in conjunction with CSK, or on its own. (Also called "CSK".)

Persistent hyaloid artery (PHA): congenital defect resulting from abnormalities in the development and regression of the hyaloid artery. The blood vessel remnant can be present in the vitreous as a small patent vascular strand (PHA) or as a non-vascular strand that appears gray-white (persistent hyaloid remnant).

Persistent hyperplastic primary vitreous (PHPV): congenital defect resulting from abnormalities in the regression of the hyaloid artery (the primary vitreous) and the interaction of the blood vessel with the posterior lens capsule/cortex during embryogenesis. This condition is often associated with congenital cataracts and frequently seen with PHTVL.

Persistent hyperplastic tunica vasculosa lentis (PHTVL): congenital defect resulting from failure of regression of the embryonic vascular network which surrounds the developing lens. Often associated with PHPV and a patent hyaloid artery.

Persistent pupillary membranes (PPM): persistent blood vessel remnants in the anterior chamber which fail to regress normally by 3 months of age. These strands arise from the iris collaret and may bridge from iris to iris, iris to lens, iris to cornea, or form sheets of tissue in the anterior chamber.

Persistent tunica vasculosa lentis (PTVL): clinically insignificant posterior epicapsular lenticular opacities resulting from incomplete regression of the embryonic vascular network which surrounds the developing lens.

Pigmentary glaucoma: see **Ocular melanosis**

Pigmentary uveitis: see **Uveitis, pigmentary**

Pigmentary keratopathy: a condition reported in Pugs in which the cornea becomes pigmented, often resulting in vision impairment. Development of pigmentary keratopathy is associated with congenital uveal pathology – iris hypoplasia and the presence of persistent pupillary membranes – but not with other factors such as Schirmer tear test values or medial canthal entropion.

Plasmoma: see **Pannus**. Also called Atypical Pannus. Bilateral thickening and depigmentation of the nictitans due to invasion of lymphocytes and plasma cells. It may or may not be associated with corneal involvement (Pannus).

Progressive rod-cone degeneration (PRCD) (see also **PRA**): Typically refers to recessively inherited generalized loss of rod photoreceptors followed by cone degeneration. Many different genetic mutations result in a similar phenotypic presentation.

Progressive retinal atrophy (PRA): an umbrella term used to describe a group of inherited dysplastic, dystrophic, or degenerative diseases of the retinal visual cells (photoreceptors, retinal pigment epithelium, or both).

Proliferative keratoconjunctivitis: see **Nodular granulomatous episclerokeratitis**

Retinal atrophy: a non-specific term used to describe a decrease in the number and deterioration of the cells of the retina, regardless of cause.

Retinal degeneration: see **Retinal atrophy**

Retinal detachment: a separation of the neurosensory retina from the retinal pigment epithelium.

Retinal dysplasia: abnormal development of the retina present at birth. This condition is non-progressive and recognized in 3 forms: **folds, geographic, detached**.

Retinal dysplasia – folds: seen ophthalmoscopically as linear, triangular, curved or curvilinear foci of retinal folding. May be single or multiple. In puppies, retinal folds can be seen as a transient phenomenon, resolving as the eye retains maturity.

Retinal dysplasia – geographic: an irregularly shaped area of retinal development containing both areas of thinning and areas of elevation. This form may be associated with visual impairment.

Retinal dysplasia – detached: severe retinal disorganization associated with separation of the neurosensory retina from the retinal pigmented epithelium. This form results in visual impairment.

Retinopathy: any non-inflammatory condition of the retina. These conditions can usually be detected by ophthalmoscopic examination, but an electroretinogram (ERG) may be required in some instances (e.g. canine multifocal retinopathy).

Rod-cone dysplasia: an inherited retinal disease characterized by abortive or abnormal development of rods and cones. Affected animals become blind early in life, usually within the first 6 months, with the exception of *rcd4* in the Gordon and Irish Setter dogs. See specific breed pages for rod-cone dysplasia type descriptions.

Rod dysplasia: abnormal development of the visual cells resulting in vision impairment in dim light by 6 months and total blindness at 3-5 years.

Uveal cyst: a pigmented, fluid-filled epithelial-lined structure arising from the posterior iris or ciliary body epithelium. Cysts may remain attached to the pupil margin, iris, or ciliary body, or may detach and be free-floating within the anterior chamber. They may rupture and adhere to the cornea or anterior lens capsule. Uveal cysts may occur in any breed. Uveal cysts are commonly benign, although they may be associated with other pathologic conditions in various breeds.

Uveal cyst, anterior chamber: a pigmented, fluid-filled, epithelial-lined structure arising from the posterior iris or ciliary body epithelium which has detached from its site of origin and is free-floating in the anterior chamber.

Uveal cyst, ciliary body: a pigmented, fluid-filled, epithelial-lined structure arising from the ciliary body epithelium and attached to the ciliary body.

Uveal cyst, iris: a pigmented, fluid-filled, epithelial-lined structure arising from the posterior iris epithelium and attached to the iris.


Uveal melanoma: a locally invasive melanocytic neoplasm arising within the uveal tract, may be benign (melanocytoma) or malignant (malignant melanoma). Uveal melanomas are reported in higher frequency in German Shepherd Dogs and Labrador Retrievers. Inherited iris melanoma has been reported in Labrador Retrievers.

Uveitis, pigmentary: a specific form of uveitis most commonly seen in middle-aged to older Golden Retrievers. Clinically manifests early as pigment deposition in a radial fashion on the anterior lens capsule with iridociliary cysts. Later stages are associated with posterior synechia, fibrinous anterior uveitis, cataract, and ultimately glaucoma. Not associated with systemic disease; may be asymmetric in presentation.

Uveodermatologic syndrome: an immune-mediated syndrome of anterior uveitis, chorioretinitis, dermal depigmentation (vitiligo), and hair depigmentation (poliosis). A similar syndrome in humans, called Vogt-Koyanagi-Harada syndrome (VKH), is an autoimmune disease directed against melanocytes. Secondary glaucoma and/or retinal detachment are frequent complications of this disease. Seen most commonly in the Akita, Samoyed, and Siberian Husky breeds.

Vitreous degeneration: Liquefaction of the vitreous gel which may predispose to retinal detachment resulting in blindness.

Y-suture tip opacity: These are prominent (or “highlighted” or “more dense”) distal portions of the posterior sutures that may occur in the posterior cortex to occasionally on the posterior lens capsule. This is not a true cataract, so there is no lens fiber disruption (no feathering or bulbous tips). It may be in the shape of a “peace sign” as diagrammed here, but occasionally a patient may have 4-5 suture lines and therefore more suture tip opacities. They may be present only at one suture tip of one eye or up to all three (or more, as stated above) suture tips in both eyes in a given dog. They are more commonly found in multiples or at least bilaterally symmetrical. They may be visible only with biomicroscopy or sometimes with retroillumination. They do not appear to progress (unless mis-diagnosed) and are considered essentially a variation of normal or possibly familial, as they are seen more commonly in certain breeds.



AFFENPINSCHER

	DISORDER	INHERITANCE	REFERENCE	BREEDING ADVICE
A.	Distichiasis	Not defined	1	Breeder Option
B.	Persistent pupillary membranes - iris to iris	Not defined	1	Breeder option
C.	Corneal dystrophy - epithelial/stromal	Not defined	1	Breeder option

Description and Comments

A. Distichiasis

Eyelashes abnormally located on the eyelid margin which may cause ocular irritation. Distichiasis may occur at any time in the life of a dog. It is difficult to make a strong recommendation with regard to breeding dogs with this entity. The hereditary basis has not been established although it seems probable due to the high incidence in some breeds. Reducing the incidence is a logical goal. When diagnosed, distichiasis should be recorded; breeding discretion is advised.

B. Persistent pupillary membranes (PPMs)

Persistent blood vessel remnants in the anterior chamber of the eye which fail to regress normally by 3 months of age. These strands may bridge from iris to iris, iris to cornea, iris to lens, or form sheets of tissue in the anterior chamber. The last three forms pose the greatest threat to vision and when severe, vision impairment or blindness may occur.

C. Corneal Dystrophy - epithelial/stromal

A non-inflammatory corneal opacity (white to gray) present in one or more of the corneal layers; usually inherited and bilateral.

References

1. ACVO Genetics Committee and/or Data from OFA All-Breeds Report.